

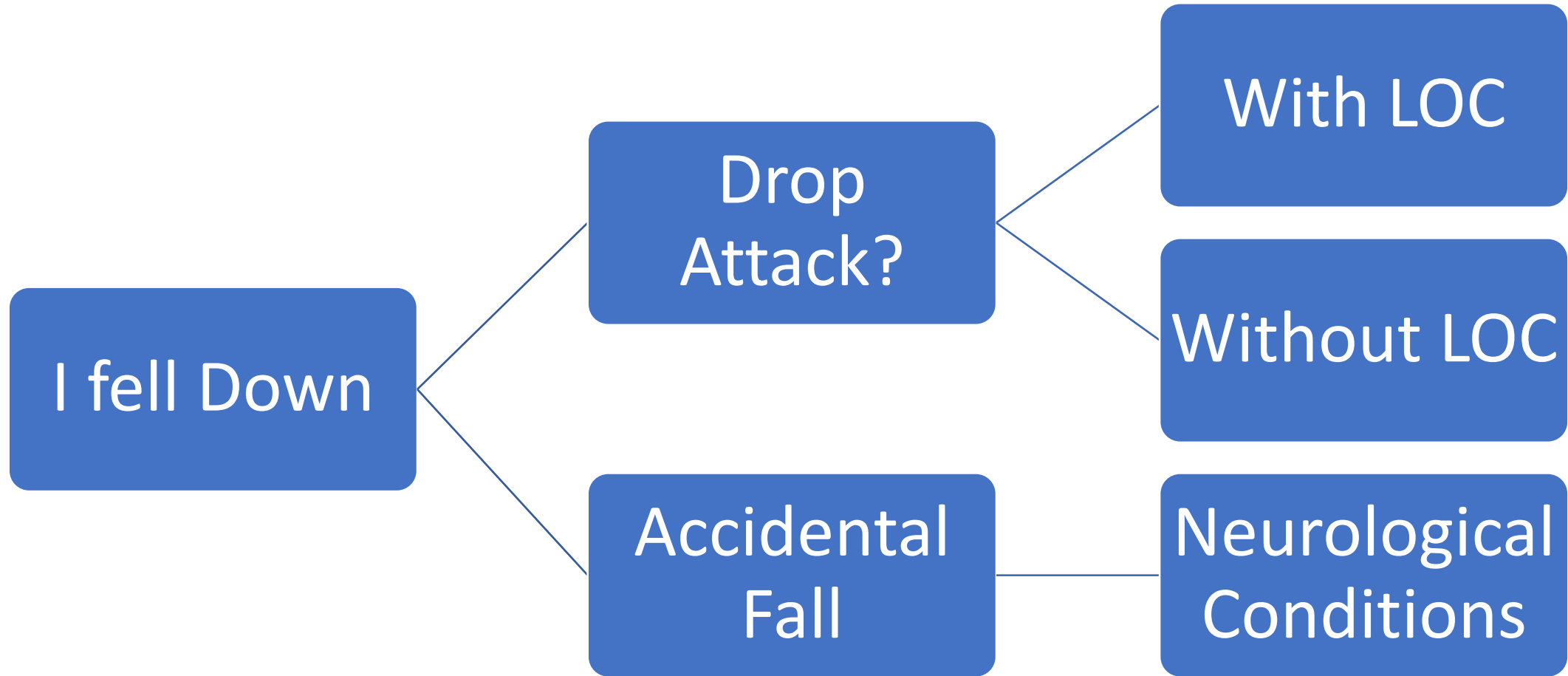
Investigating Falls with or without LOC

Hrishikesh Kumar

Institute of Neurosciences, Kolkata

Is it Drop Attack or Accidental Fall?

- Drop Attack: Sudden unexpected fall occurring with or without loss of Consciousness
- Accidental Fall: Inability to remain upright due to Postural Challenge; usually seen in chronic Neurological condition



Drop Attack with Loss Of Consciousness

- Epileptic Event
- Syncopal Episodes

Drop Attack without Loss Of Consciousness

- TIA
- Third ventricular or Posterior fossa abnormalities
- Otolith Crisis

Drop Attack with Loss of Consciousness

	Syncope	Seizures
Relation to Posture	Common	No
Skin colour	Pale	Cyanosis +/-
Aura	Longer	Brief
Convulsion	Rare	Common
Urinary incontinence	Rare	Common
Tongue bite	No	Common
Post-ictal Confusion	Rare	Common
Injury	Rare	Common

Drop Attack without Loss of Consciousness

Transient Ischemic Attack:

- Vertebro-basilar- Often has associated Diplopia, Vertigo, Vomiting
- ACA: Legs give way

Third Ventricular lesion: Usually Colloid Cyst (Can be associated with Position induced Headache)

Posterior fossa lesion: Chiari malformation, Tumor

Otolith Crisis (Vestibular Drop Attacks) or Tumarkin Otolith Crisis: Meniere's Disease; Unilateral Vestibulopathy not satisfying the diagnostic criteria of Meniere's disease

Accidental Fall due to Neurological illness

Fall pattern

- Tripping
- Collapsing (falls like a heap)
- Toppling (falls like a log of tree)

Beware of Episodic gait disorder

- Freezing, festination, Dysequilibrium, Paroxysmal dystonia

Tripping fall

- Feet do not clear the surface adequately
- Falls are generally forward
- Foot drop, spasticity, Foot Dystonia, Parkinsonism

Collapsing fall

- Akinetic Seizure
- Syncope
- Orthostatic Hypotension
- Parkinson's Disease
- Multisystem Atrophy



Toppling fall- muscle tone preserved

- Patient falls like a falling tree
- Standing: Progressive Supranuclear Palsy, Thalamic Astasia
- While changing position or posture: Parkinson's Disease