

**17th Workshop on
NEUROTOLOGY and
MEDICAL AUDIOLOGY**

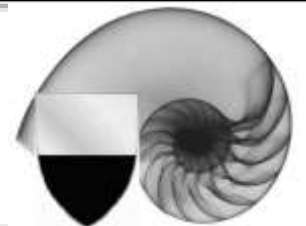
Kolkata : 19th to 21st Jan, 2018

THE FUNCTIONAL HEAD IMPULSE TEST (FHIT)

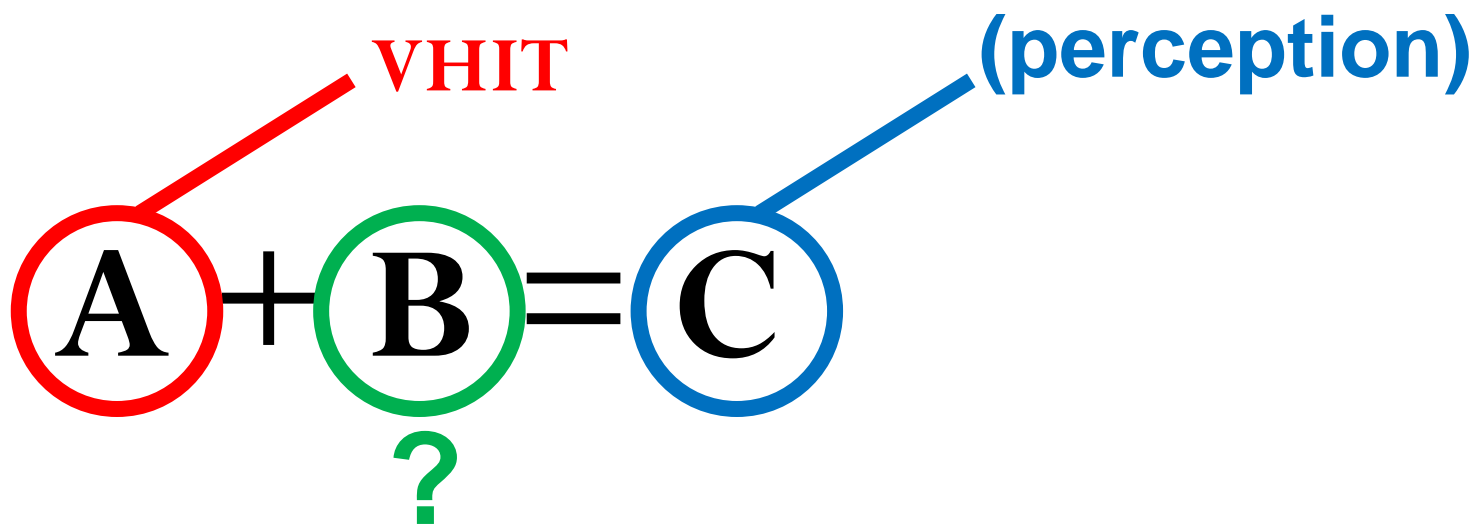
Marco Mandalà



Otology and Skull Base Surgery Department
University of Siena, Italy



In case you were the last audiologist on an remote island would you prefer to have with you the pure tone or speech audiometry?

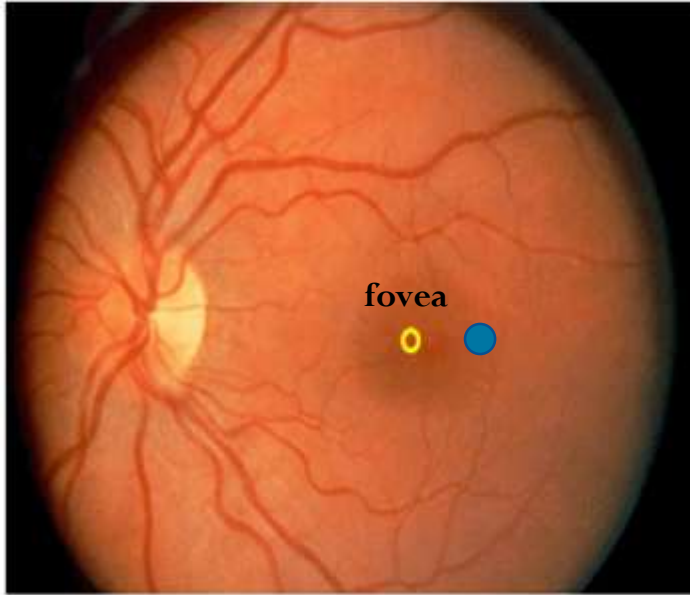


Vestibulo Ocular Reflex (VOR)

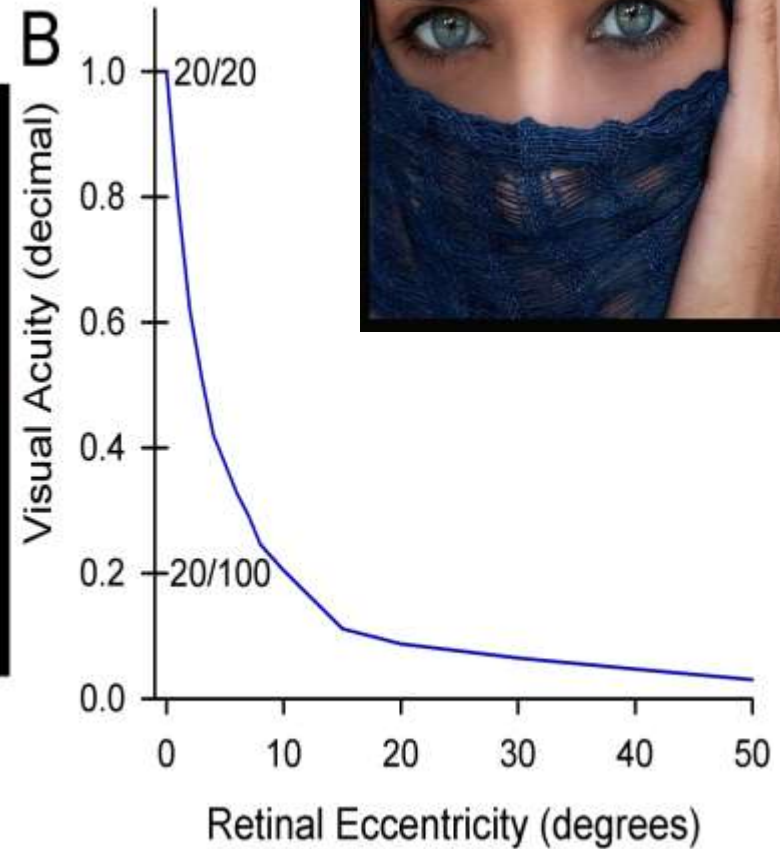
- VOR: enables clear vision by stabilizing gaze (eye position in space) during head movements (mediated by six SCCs)
- Locomotion: head movements with predominant high frequencies (0,5 to 5.0 Hz) and accelerations (4.000 deg/s² and above)
- VOR: rapidly acting reflex with short latency (7-15 ms) - fast enough to generate eye movements that compensate for these frequencies
- Latency of visual-mediated eye movements in humans too slow (75 ms)
- Function of the angular VOR: to hold images on the retina during head rotations... to allow perception!

Da Leigh &
Zee

A



B



Clear vision of an object requires that its image is held steadily within 0,5 deg from the center of the fovea (greatest photoreceptor density-optimal visual acuity)

2 degrees from the center of the fovea, visual acuity declines by about 50%.

VOR impairment

- *Poor gaze stabilization during head movements*
- *Impairment of vision when walking*
- *Dizziness/instability*



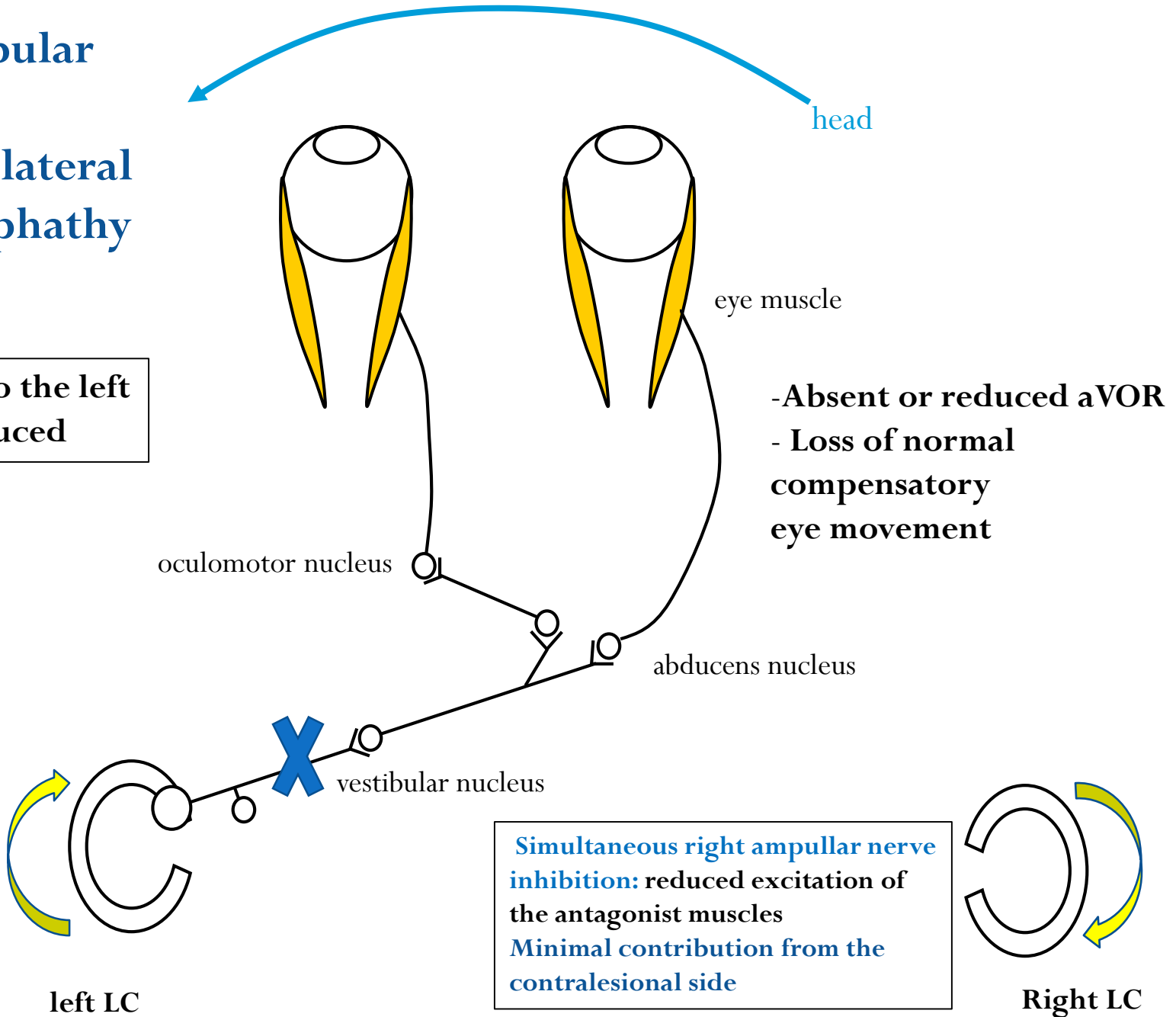
aVOR assessment: the HIT

- **A clinical sign of canal paresis.** (Halmagyi & Curthoys, Arch Neurol 1988)
- Revolution in the evaluation of vestibular disease
- Aw et al. (1996): scleral search coil HIT
- MacDougall et al.(2009): The Video HIT (Lightweight high speed video system – objective measurement)



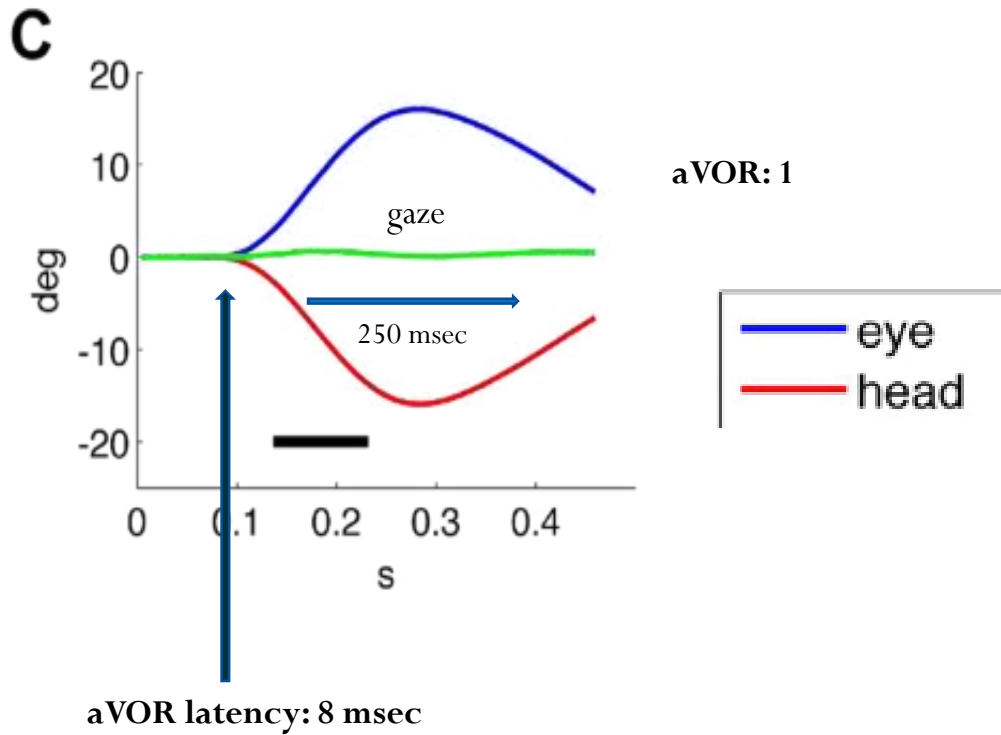
Left vestibular neuritis – Acute unilateral vestibulopathy

-Head turn to the left is not transduced

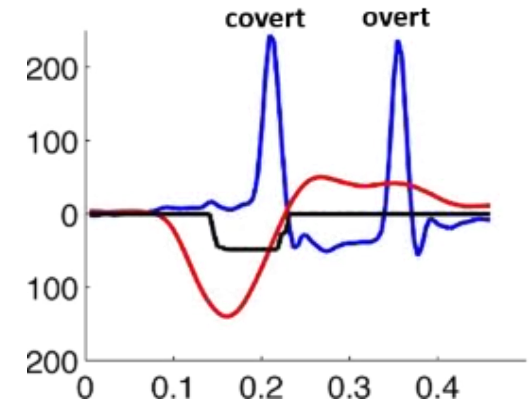


Video HIT: ocular response (yaw axis)

normal



Vestibular neuritis



Dynamic Visual Acuity Test



Normal subjects lose only 1 line of acuity with head shaking. Patients with no vestibular function lose about 5 lines with horizontal or vertical rotation but not with rotation in 'roll' (ear to shoulder) since the image is still on the fovea. Patients who lose DVA in 'roll' are malingering!


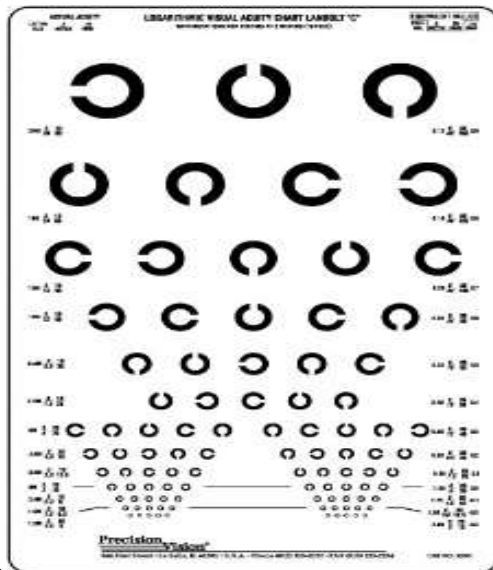
Functional HIT

- Perceptive test
- Does not measure the eye movements
- Assess the *function* of angular VOR at high acceleration/velocity
- Determines the ability to keep an image into focus when HIT is performed at different head accelerations and velocities

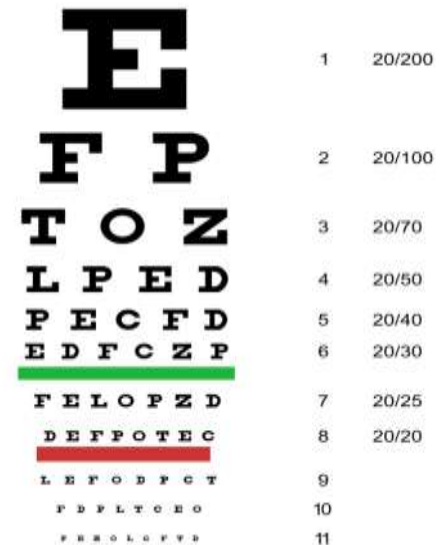
Functional HIT

- Measure of the ability to read an optotype briefly shown on the screen during head acceleration
- The patient must recognize the orientation of the Landolt C optotype with random orientation
- or a alphabet letter of the Snellen chart (Disney characters for children!)

Landolt C chart



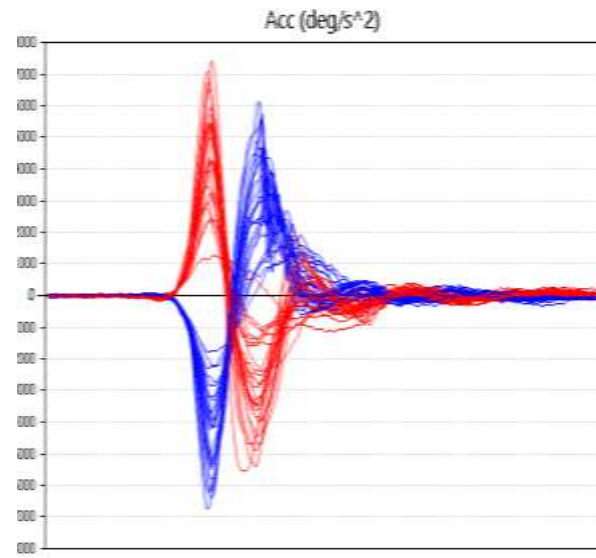
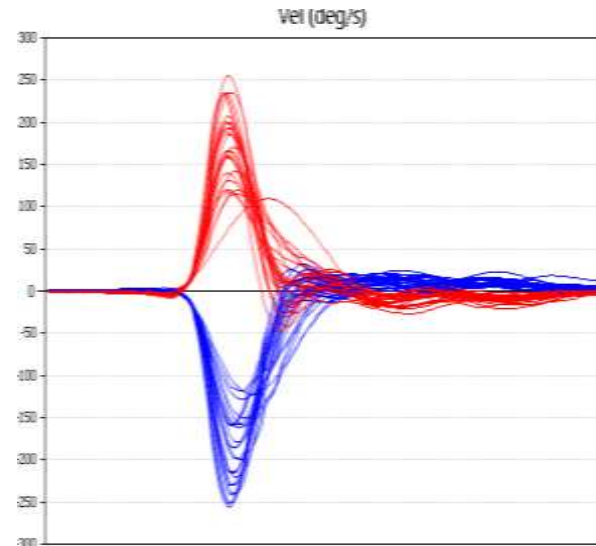
Snellen chart for visual acuity



Functional HIT

The **measure of static visual acuity** allows to normalize the size of the visual stimulus so that the letters shown were 0.6 logMAR lines larger.

The imposed head thrusts have different head accelerations, **classified in acceleration bins** (width of $1000^\circ / s^2$ with upper bounds ranging 2000–7000/ s^2) based on their direction.

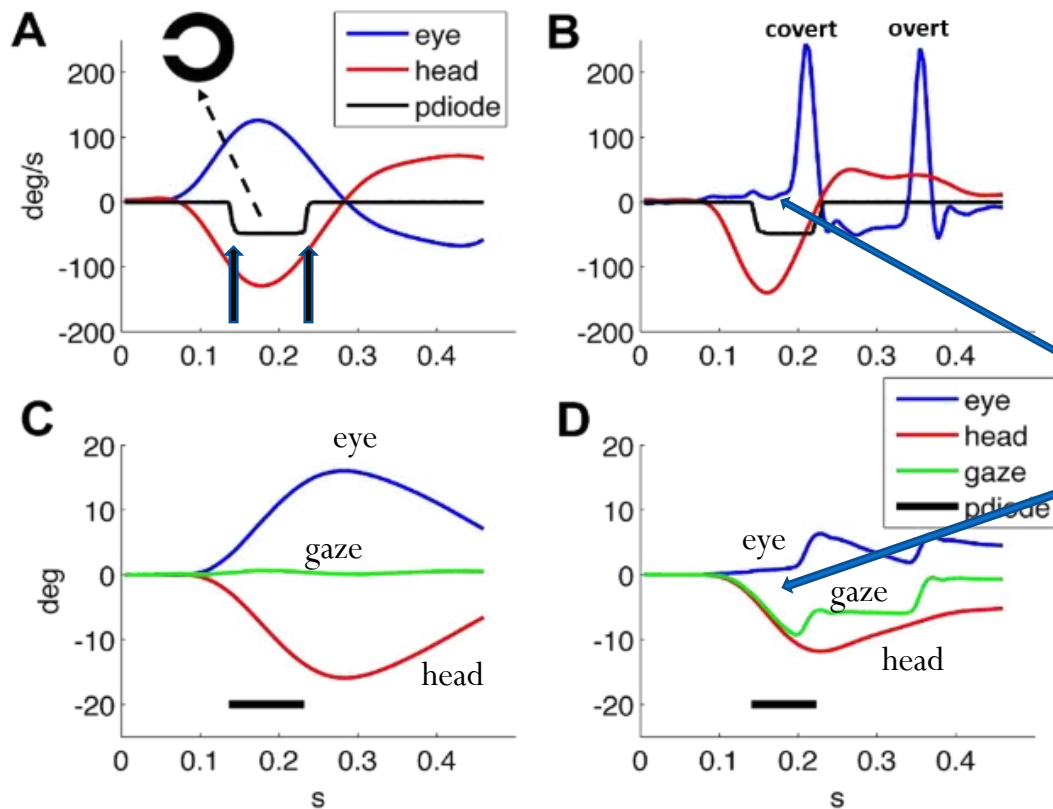


Functional Head Impulse Test (summary)

1. The **measure of static visual acuity** allows to normalize the size of the visual stimulus so that the letters shown were 0.6 logMAR lines larger.
2. An **optotype** with random orientation was shown during the head impulse based on head angular acceleration.
3. Patients were asked to recognize the shown letter.
4. Different head accelerations: the imposed head thrusts are **classified in acceleration bins** (width of $1000^\circ/\text{s}^2$ with upper bounds ranging 2000–7000/ s^2) based on their direction.

✓ Outcome % correct answers (Y axis) vs range of head accelerations (X axis).

fHIT



Optotype
presentation
period: around
80 msec

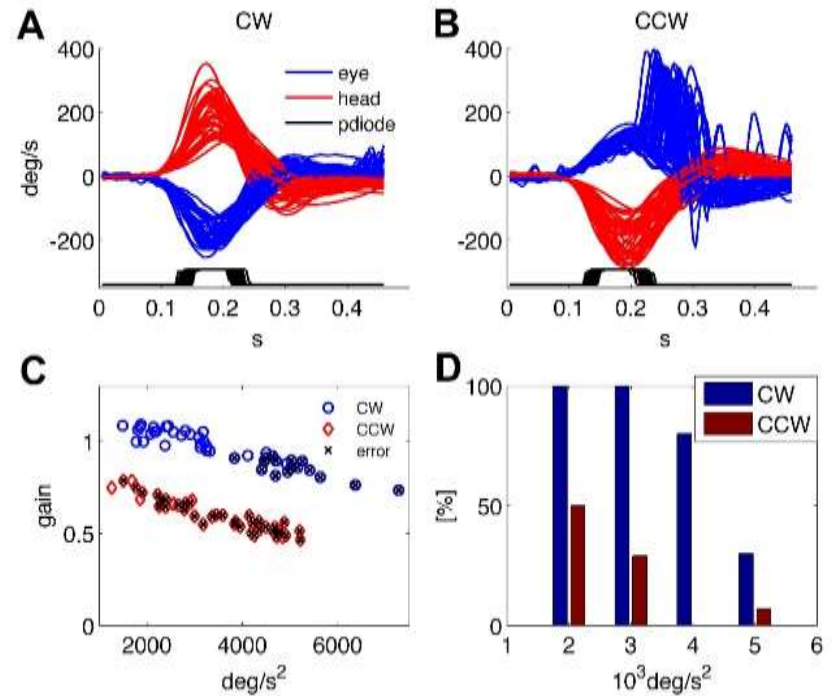
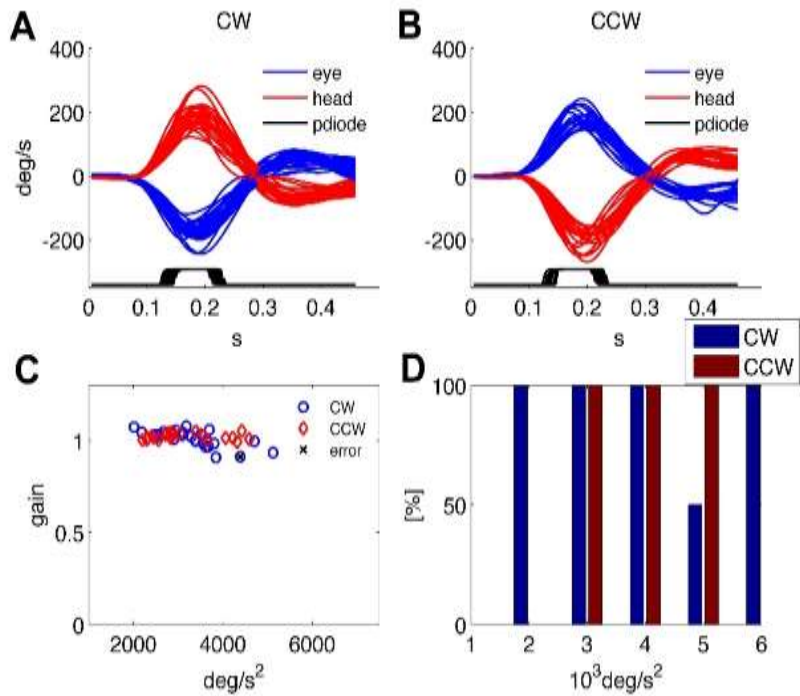
Impaired vision

Colagiorgio et al. "A new tool for investigating the functional testing of the VOR". Front. Neurol. 4:165, 2013.

Validation with VHIT

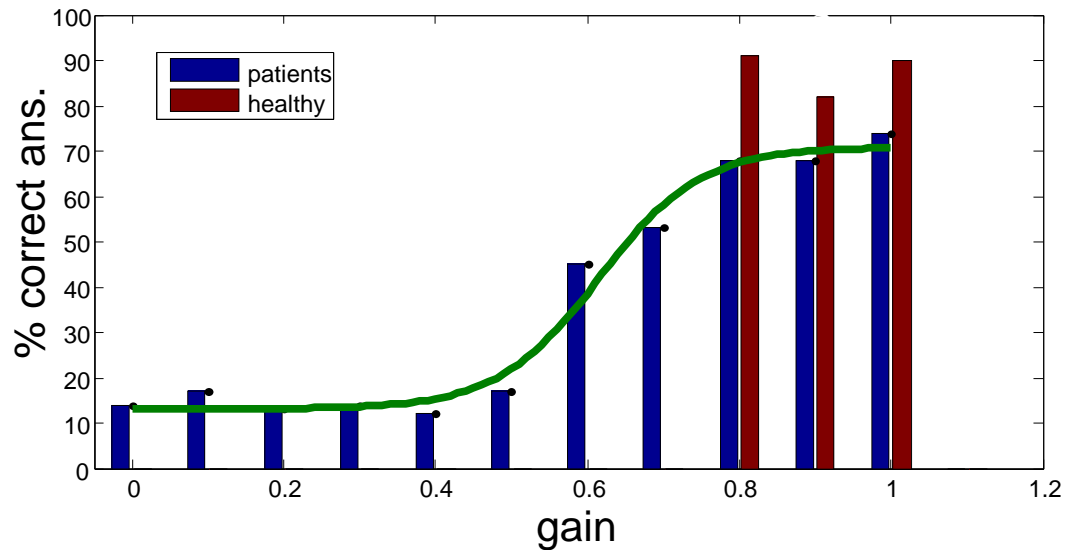
Healthy subject

Vestibular Neuritis – Acute Unilateral Vestibulopathy

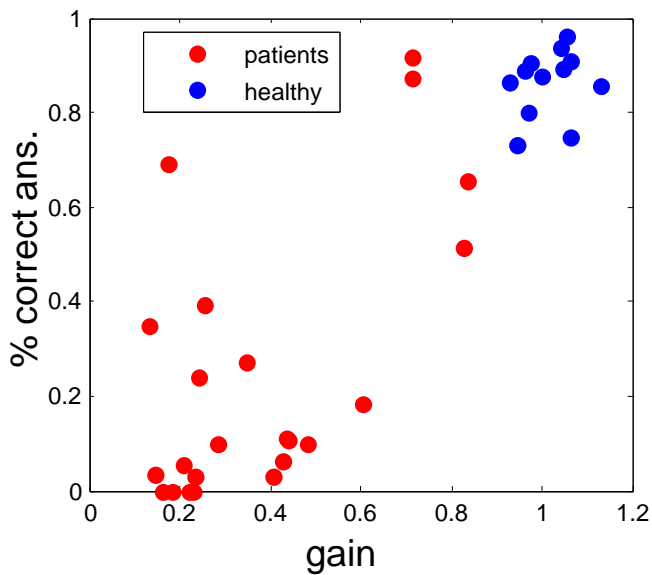


Versino M, Colagiorgio P, Sacco S, Colnaghi S, Quagliari S, Manfrin M, Benazzo M, Moglia A, Ramat (2014) *S. Reading while moving: The functional assessment of VOR*. Journal of Vestibular Research, 24(5).

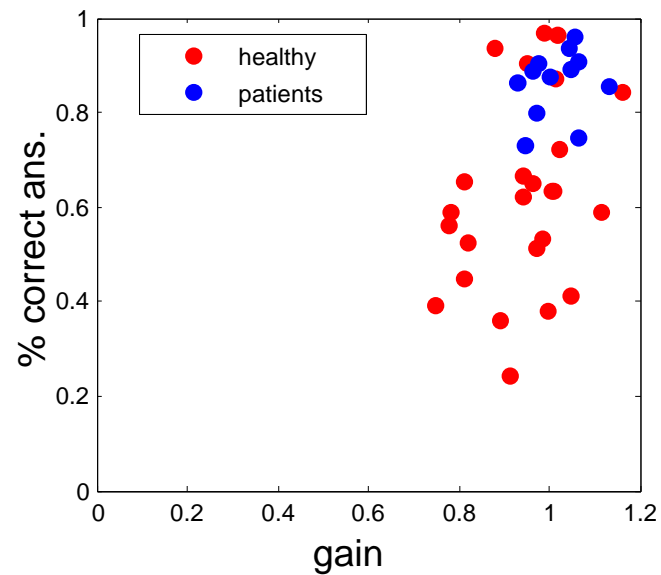
Validation with VOG



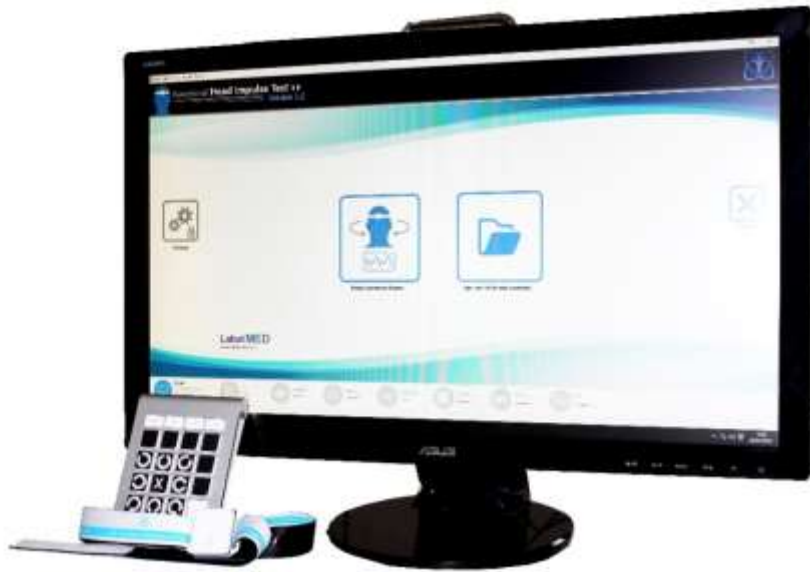Ipsilateral



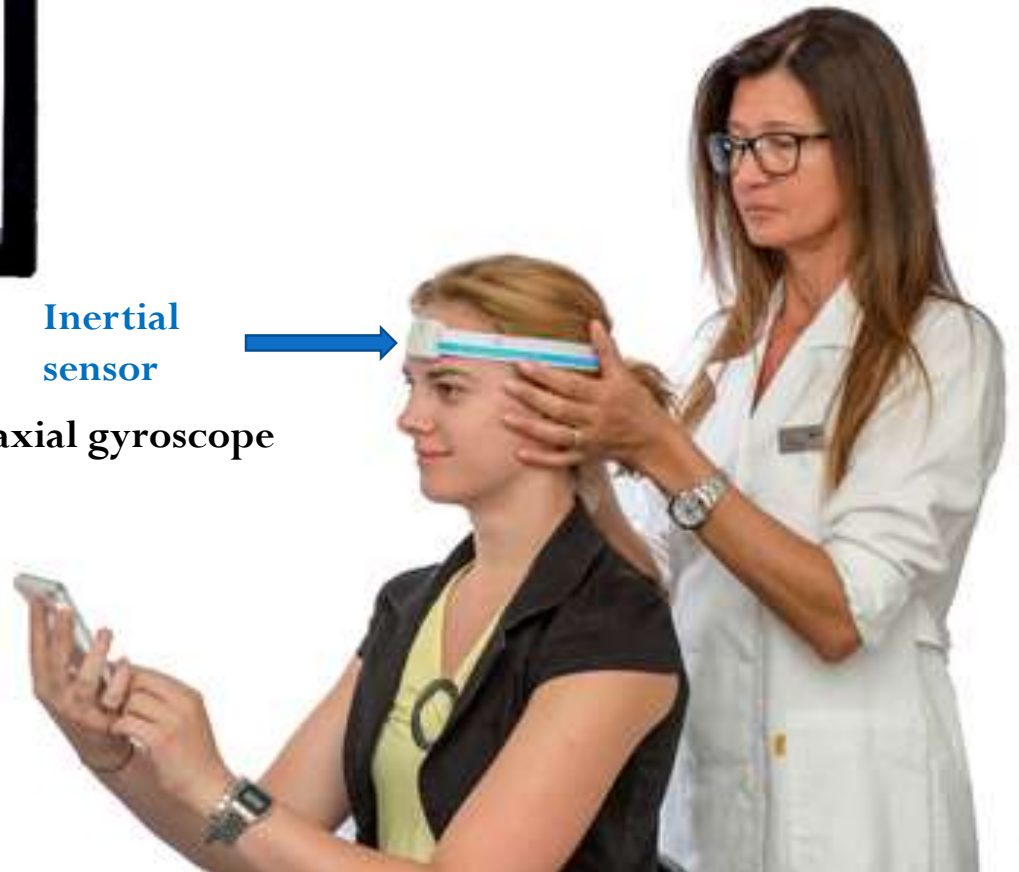
contralateral




Functional Head Impulse Test



Inertial
sensor
3 axial gyroscope

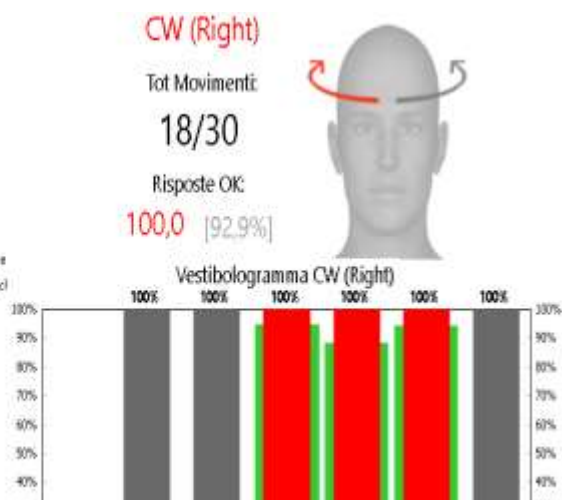
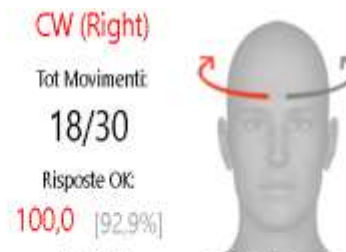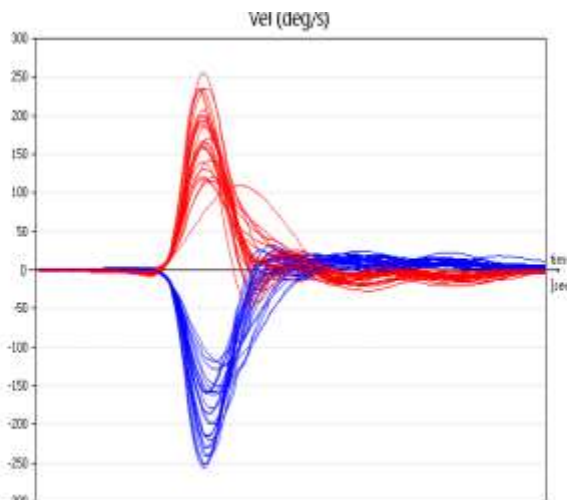

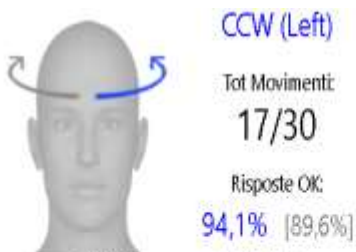
FHIT: FUNCTIONAL HEAD IMPULSE TEST ...the beginning

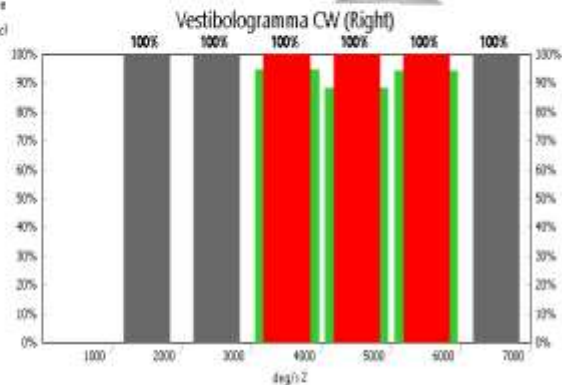
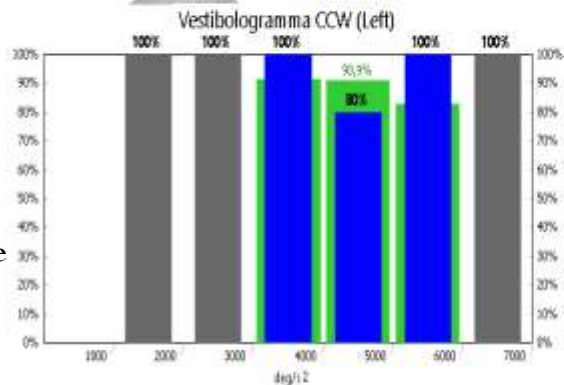




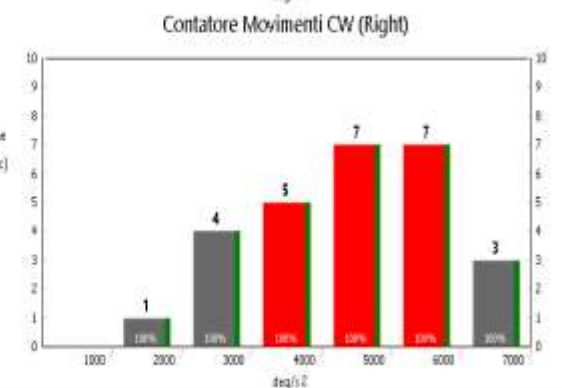
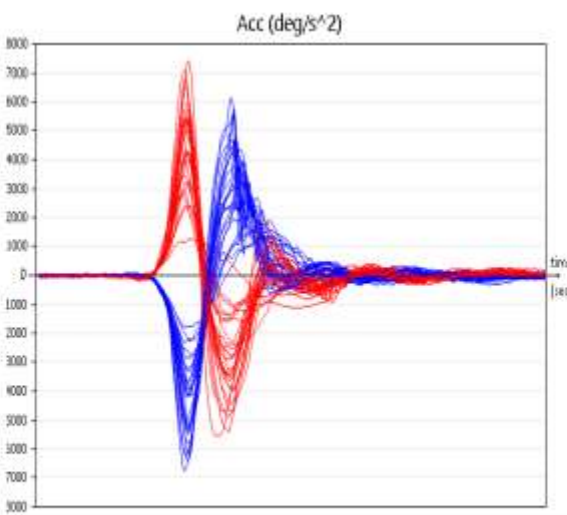
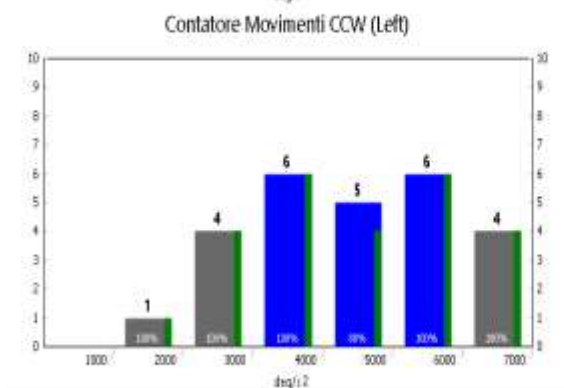
Test Outcome = % correct answers



Score
 Percentage
 of correct re-
 sponses



N° head
 impulses



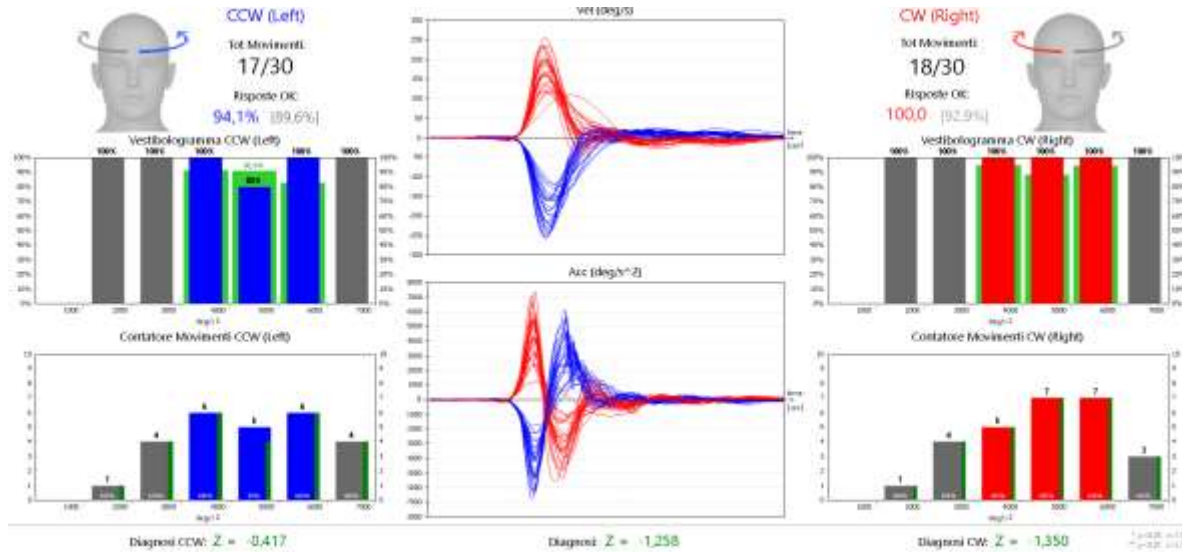
Diagnosi CCW: Z = -0,417

Diagnosi: Z = -1,258

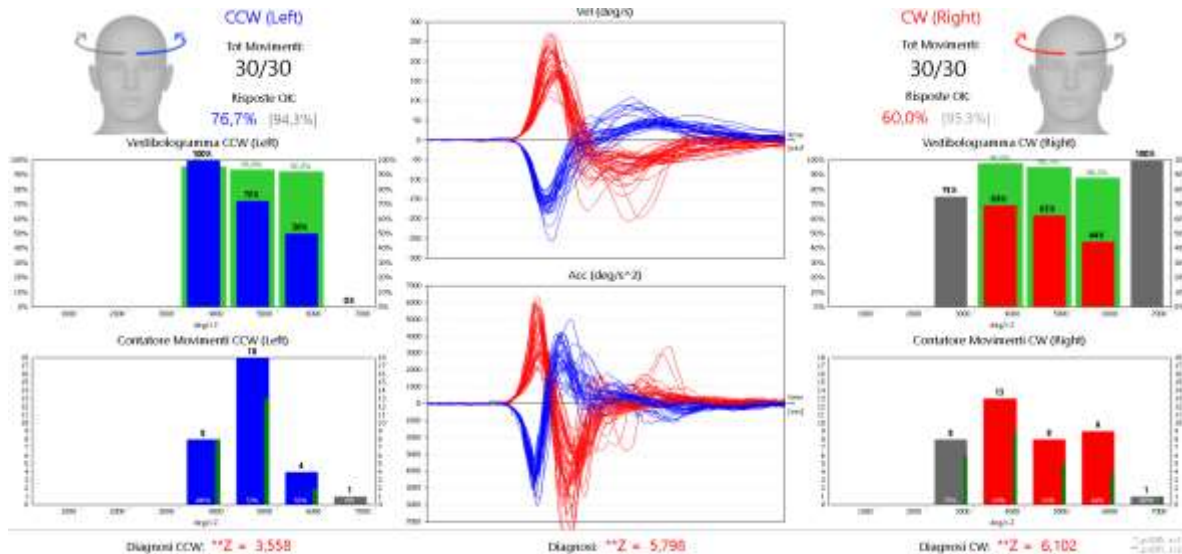
Diagnosi CW: Z = -1,350

* p < 0,05, ** p < 0,01, *** p < 0,001

Functional Head Impulse Test



Healthy subject



Patient

Conclusions

- FHIT is a complementary test to assess vestibular function (like speech audiometry and pure tone audiometry)
- Does not require eye movements analysis
- Easy and fast (10 minutes) – patient clear insight of the disorder
- Paediatric patients
- “Small eyes” people
- With glasses (?)
- Good correlation with patient perception of the disorder (bilateral VL...)
- New perspectives: vestibular neuropathy, presbiastasis, vestibular migraine...
- Rehabilitation

**Functional
Head
Impulse
Test**



Stefano Ramat



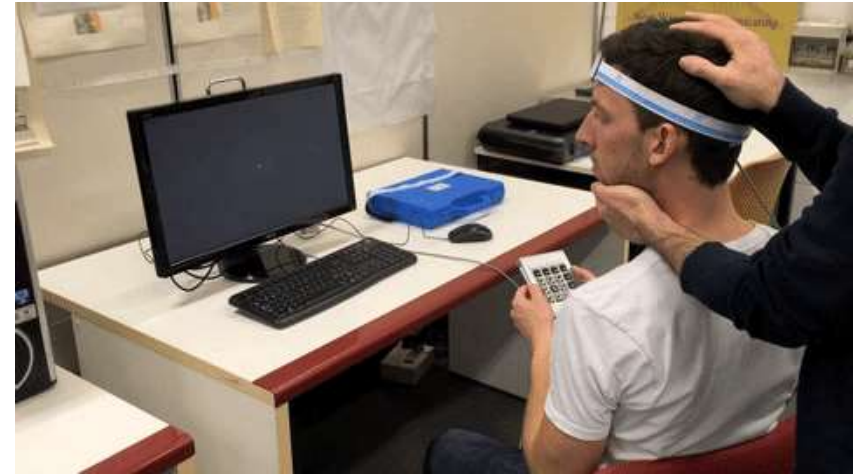Marco
Mandalà



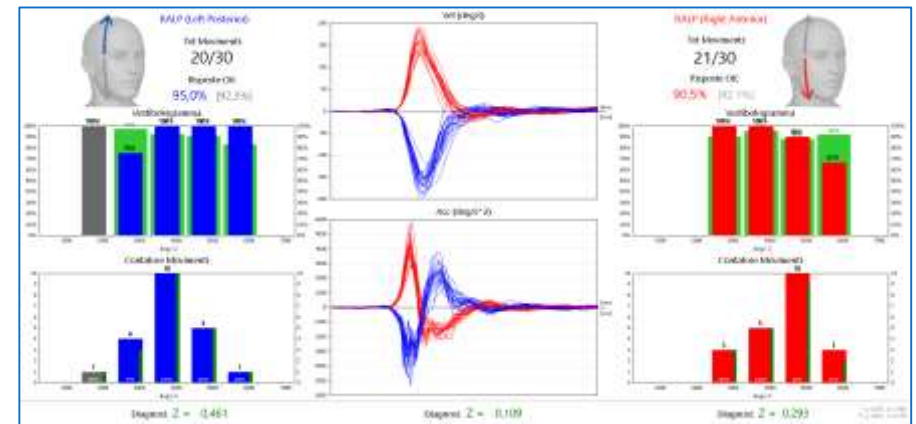
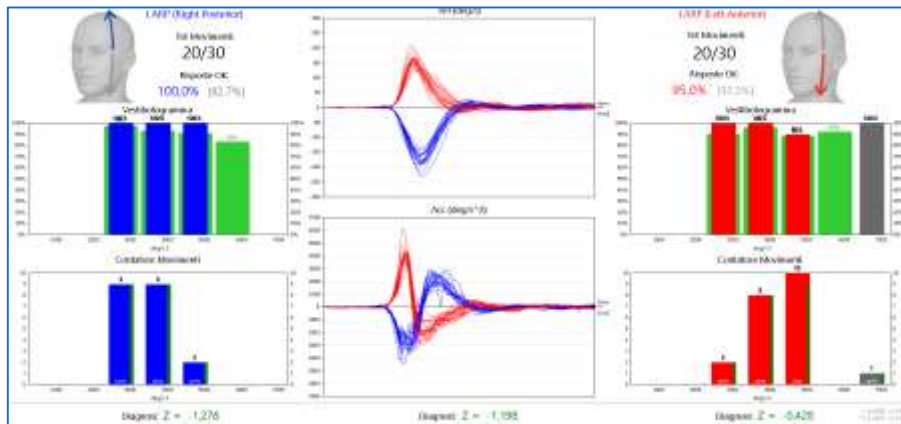
Maurizio
Versino



LARP



RALP



LEFT ACUTE VESTIBULAR NEURITIS

Data referto: 15/05/2017

Operatore referto: utente utente

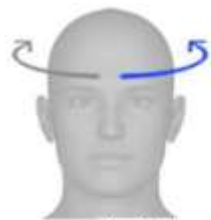
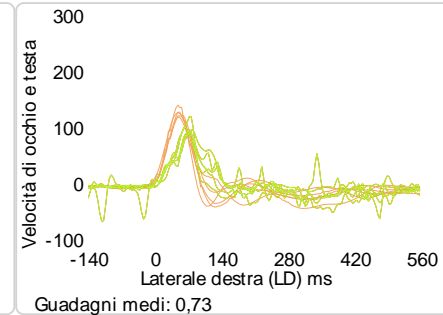
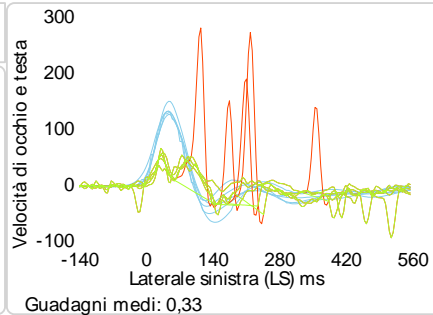
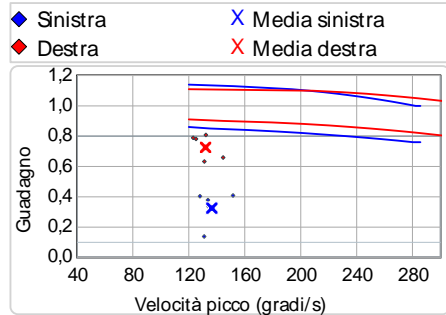
Impulso della testa

Prova impulso laterale: 05/04/2017 12:02:32
Operatore della prova: utente utente

\bar{x} Sinistra: 0,33, σ : 0,1

\bar{x} Destra: 0,73, σ : 0,07

Asimmetria relativa: 55%

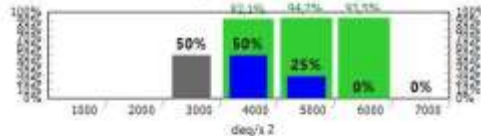


CCW (Left)

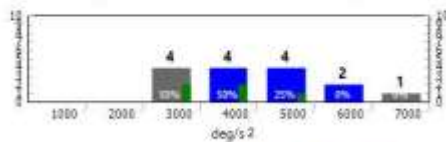
Tot Movement: 10/30

Answers OK: 30,0% [93,3%]

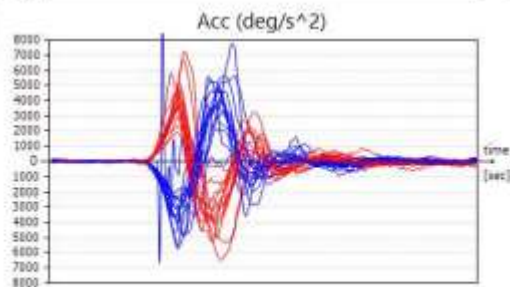
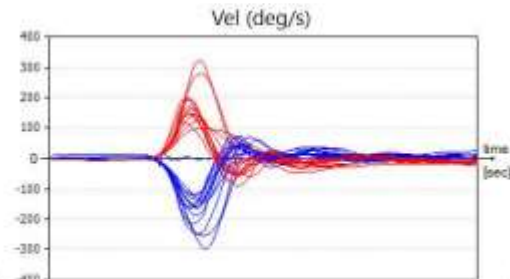
Vestibologramma CCW (Left)



Movement Counter CCW (Left)



Diagnosis CCW: ****Z = 7,624**



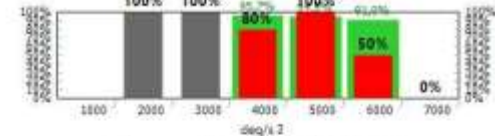
Diagnosis: ****Z = 6,413**

CW (Right)

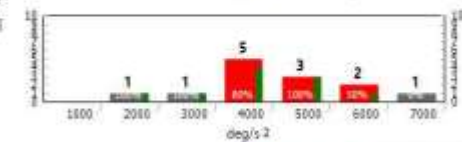
Tot Movement: 10/30

Answers OK: 80,0% [94,0%]

Vestibologramma CW (Right)



Movement Counter CW (Right)



Diagnosis CW: **Z = 1,726**
* p<0,05, n=1.983
 ** p<0,01, n=2.576

LEFT ACUTE VESTIBULOPHATY (FOLLOW-UP 3 MONTHS)

Data referto: 15/05/2017

Operatore referto: utente utente

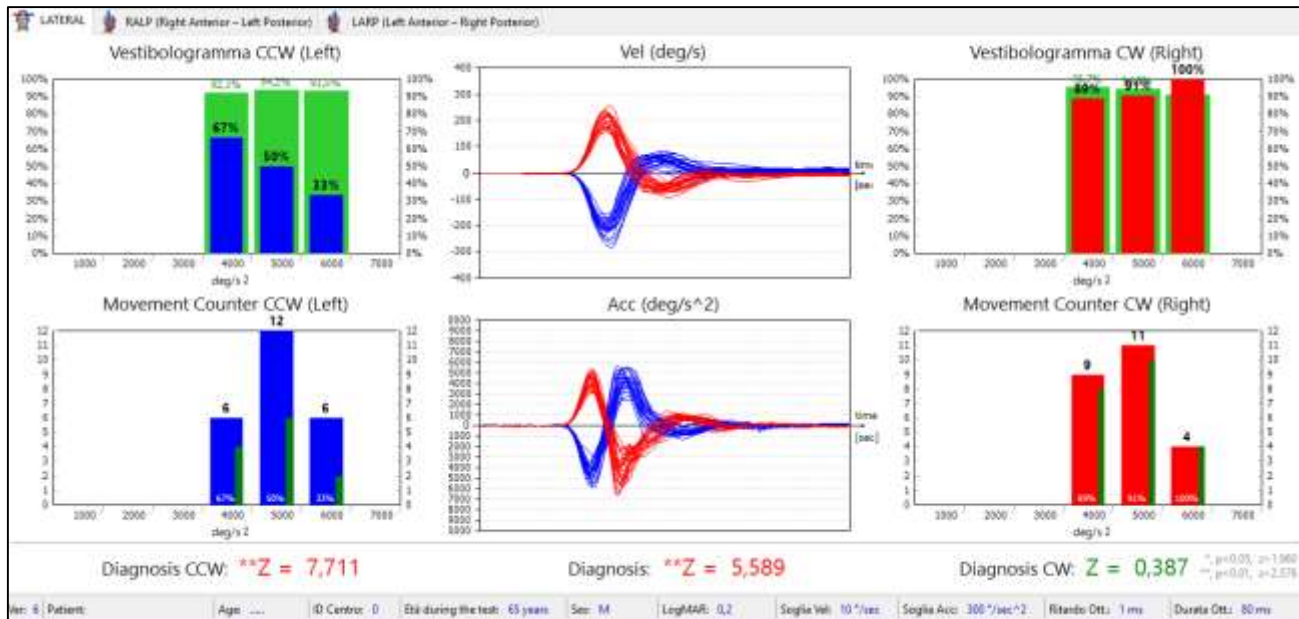
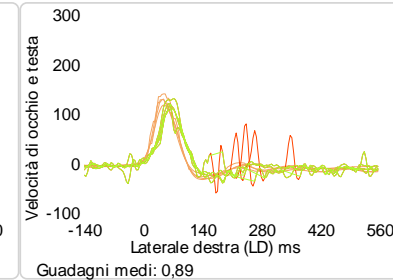
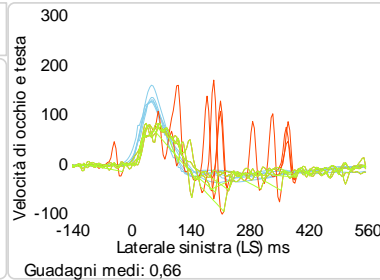
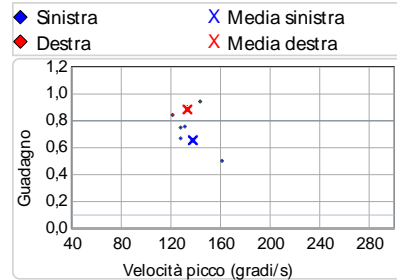
Impulso della testa

Prova impulso laterale: 26/04/2017 11:08:35
Operatore della prova: utente utente

\bar{x} Sinistra: 0,66, σ : 0,09

\bar{x} Destra: 0,89, σ : 0,04

Asimmetria relativa: 26%



LEFT VESTIBULAR NEURITIS 6 MONTHS FOLLOW-UP (RECOVERY)

Data referto: 15/05/2017

Operatore referto: utente utente

Impulso della testa

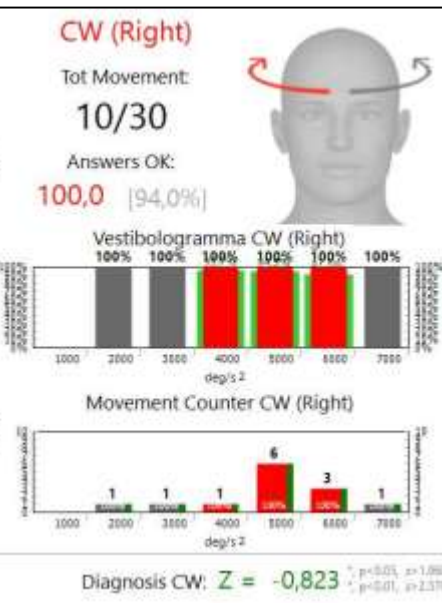
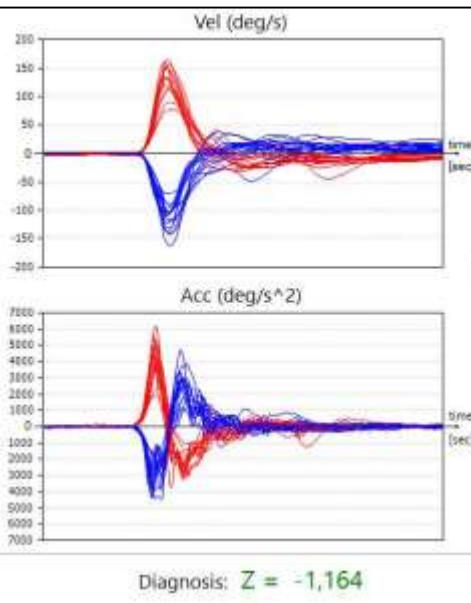
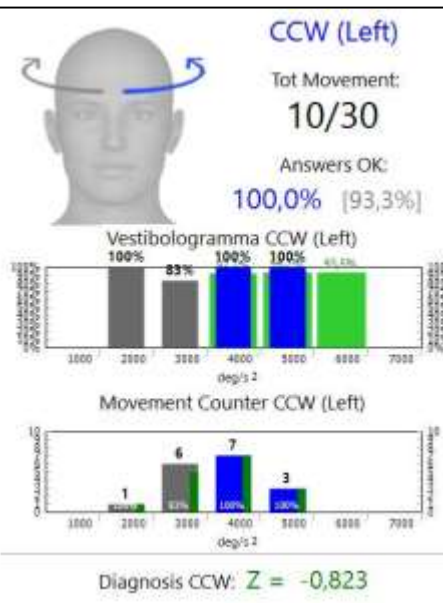
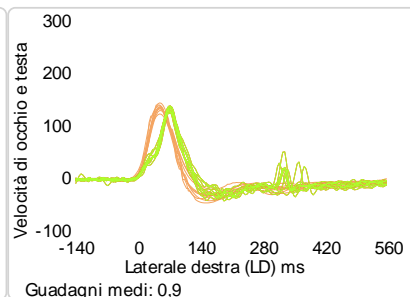
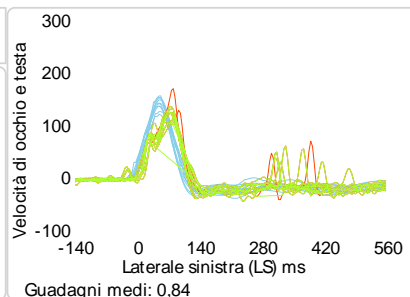
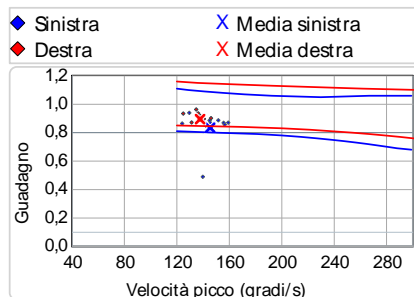
Prova impulso laterale: 05/04/2017 11:26:03

Operatore della prova: utente utente

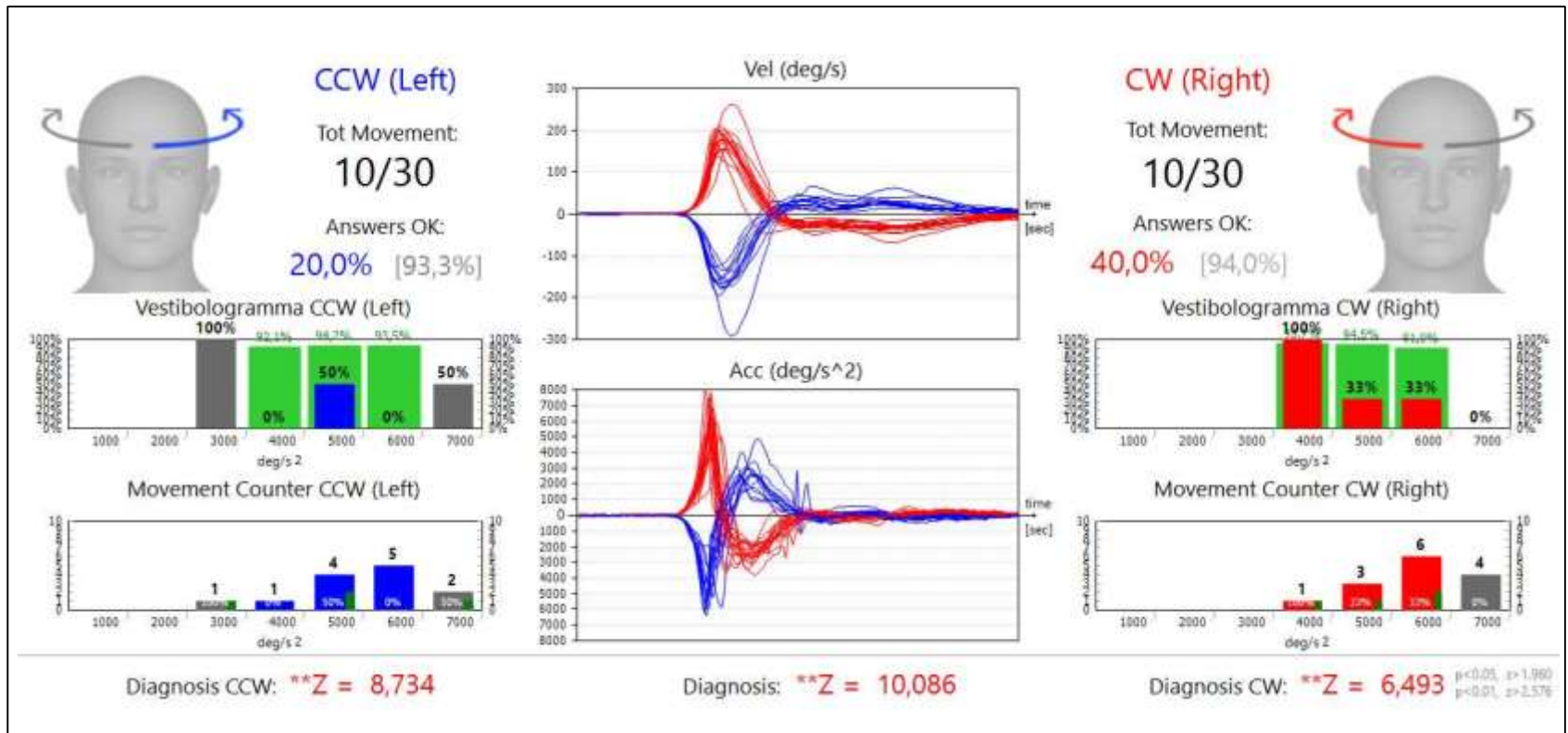
\bar{x} Sinistra: 0,84, σ : 0,12

\bar{x} Destra: 0,9, σ : 0,03

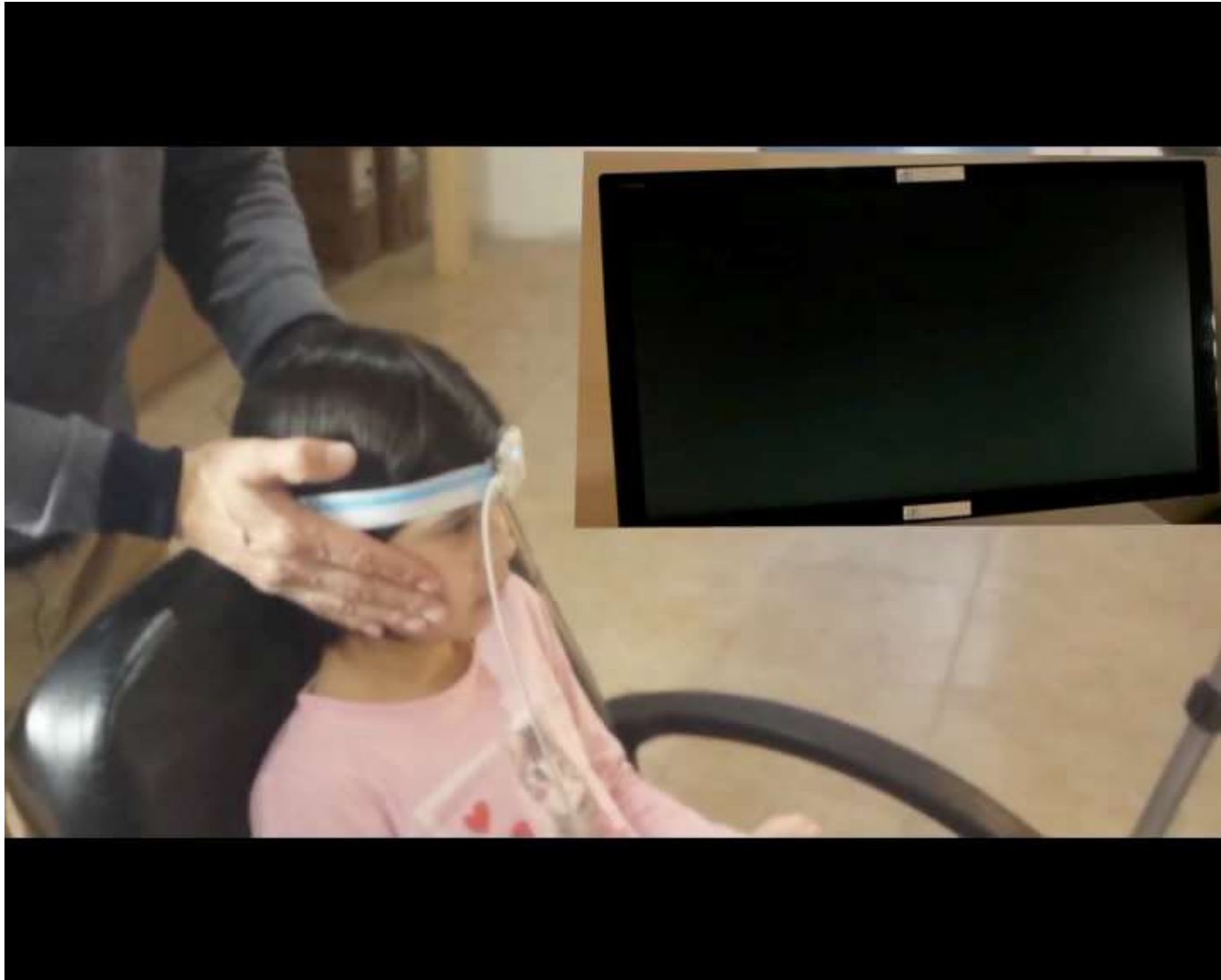Asimmetria relativa: 7%



BILATERAL VESTIBULAR LOSS



FHIT IN CHILDREN




THE ROTATING FRAME - FHIT

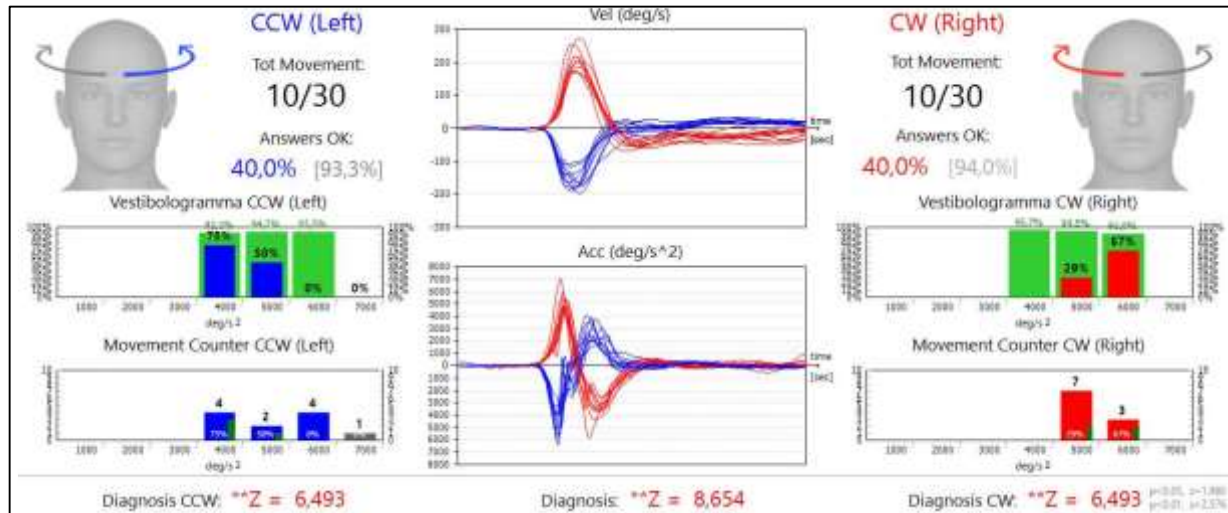
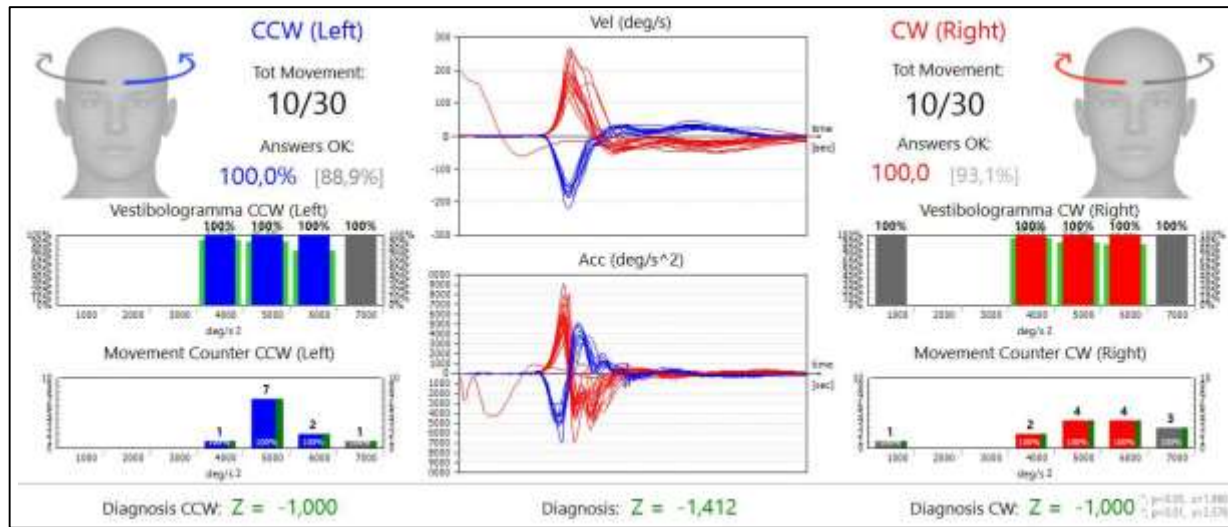
Background:

Visual Vertigo (Guerraz et al., 2001)

Postural-perceptual dizziness (Dieterich and Staab, 2016)



VISUO-VESTIBULAR NEUROPHATY in VESTIBULAR MIGRAINE



With rotating frame on

Examintion: **Spont. ny, Calorics, HST, HIT, HHT, Vibr,
VHIT, FHIT, DHI**

N° subjects: **25**

Sex (M/F): **13/12**

Age (years): **55.6±12.1**

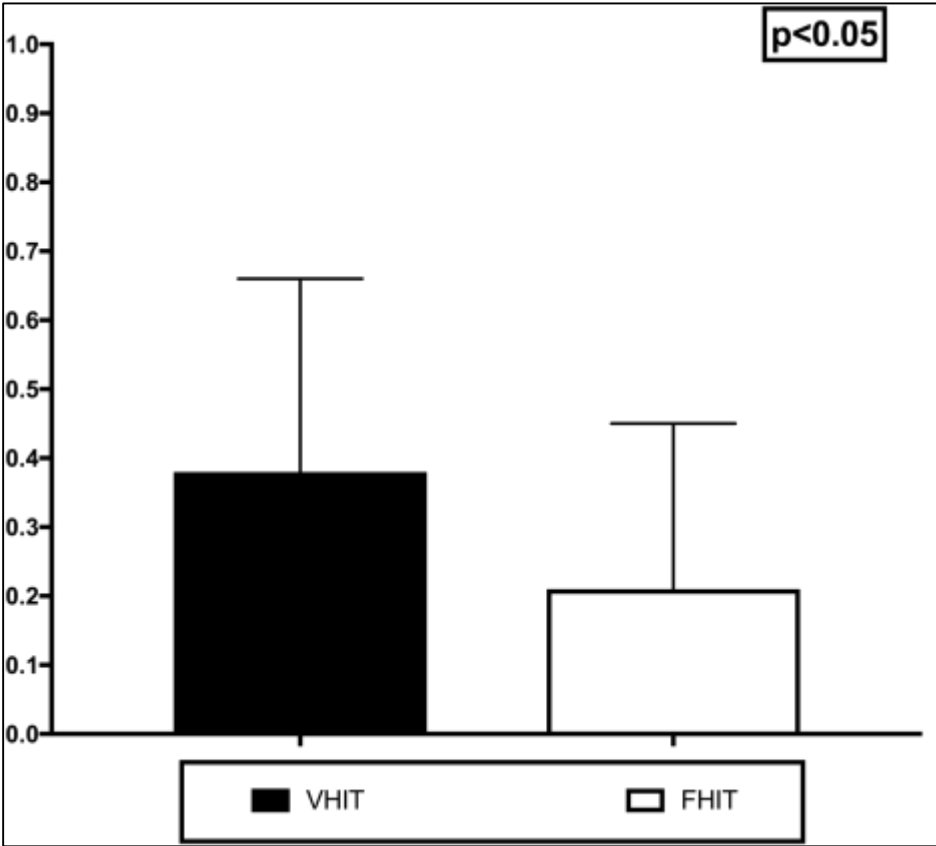
Side (R/L): **11/14**

Follow-up: **acute, 3 months**

ACUTE

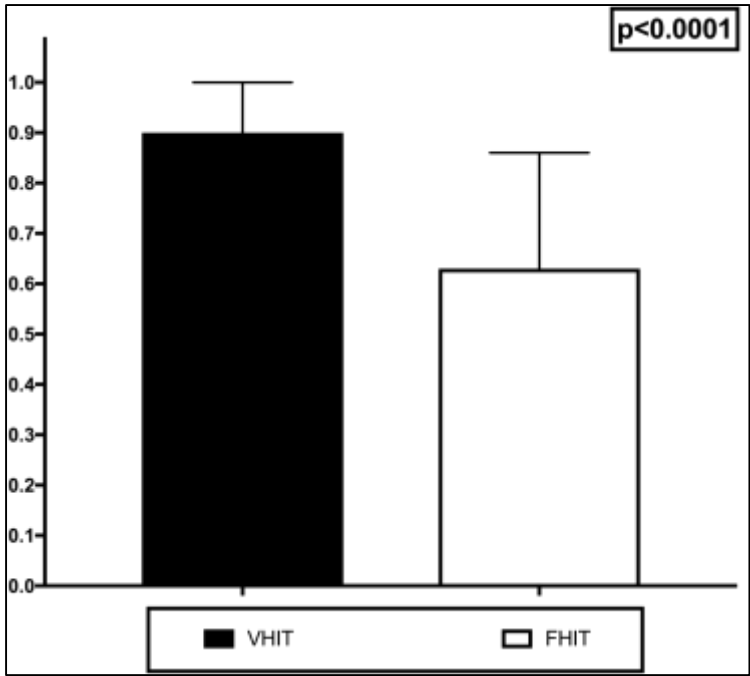
IPSI LESIONAL SIDE

p<0.05



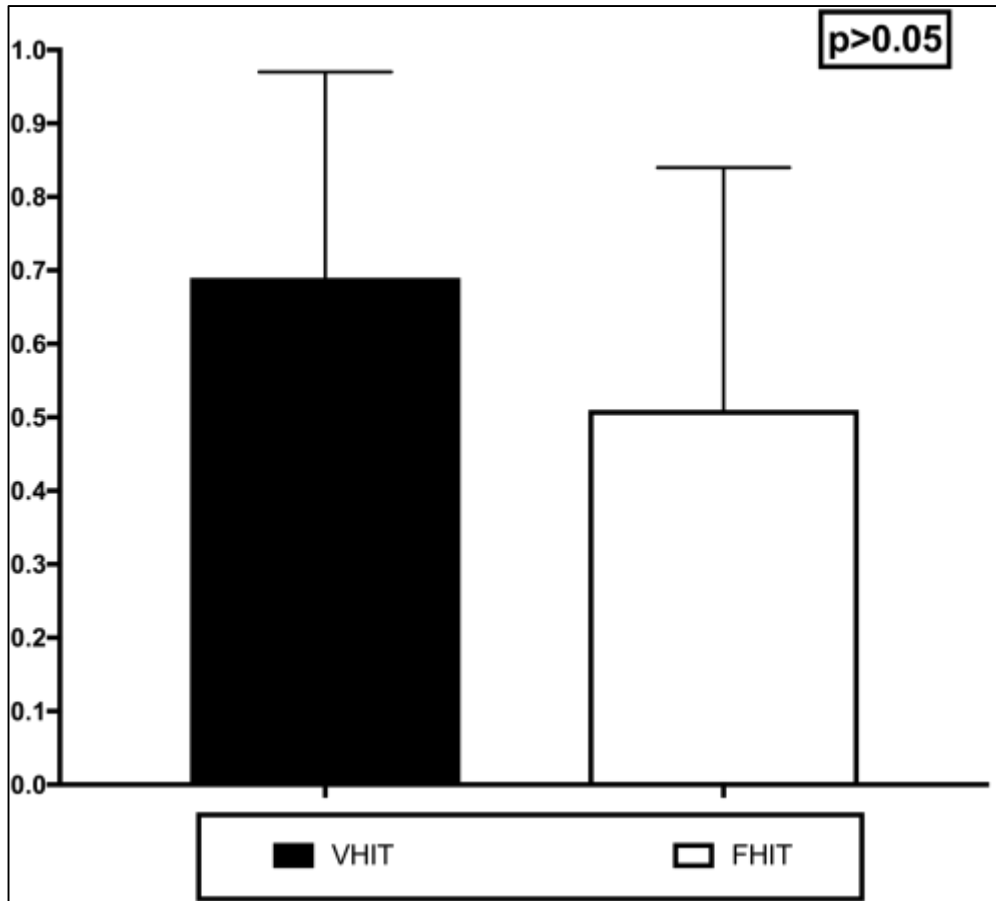
CONTRA LESIONAL SIDE

p<0.0001

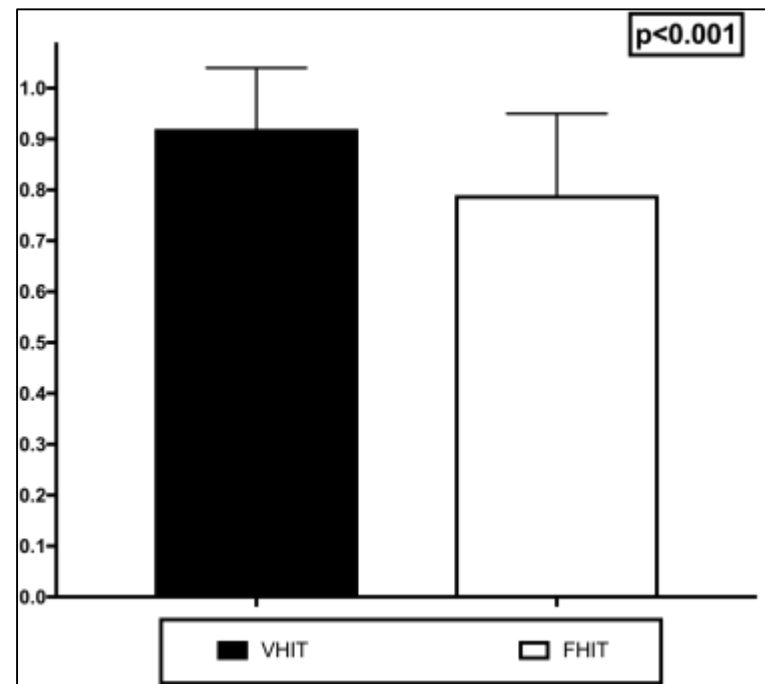


3 MONTHS FOLLOW-UP

IPSI LESIONAL SIDE



CONTRA LESIONAL SIDE

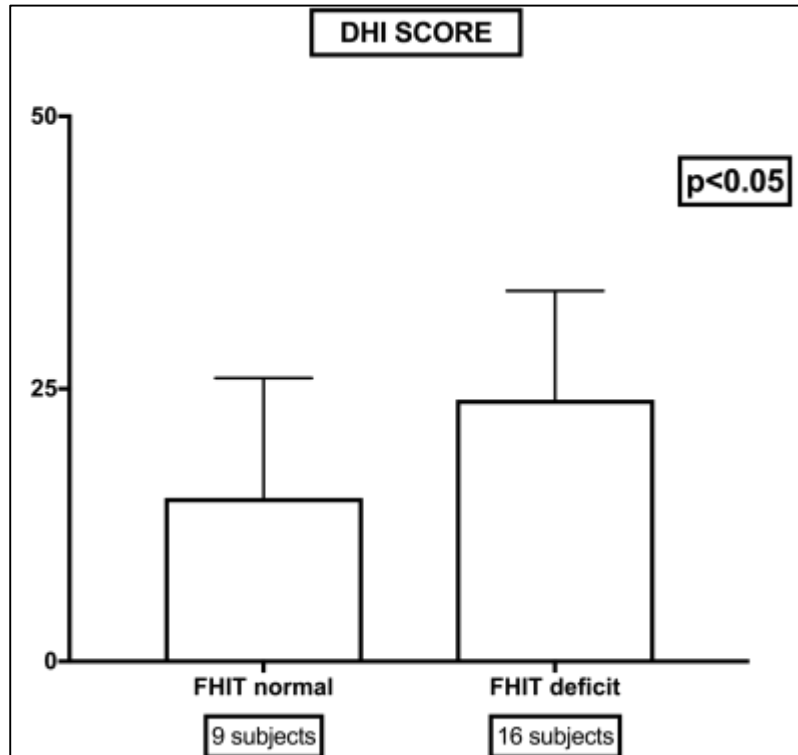
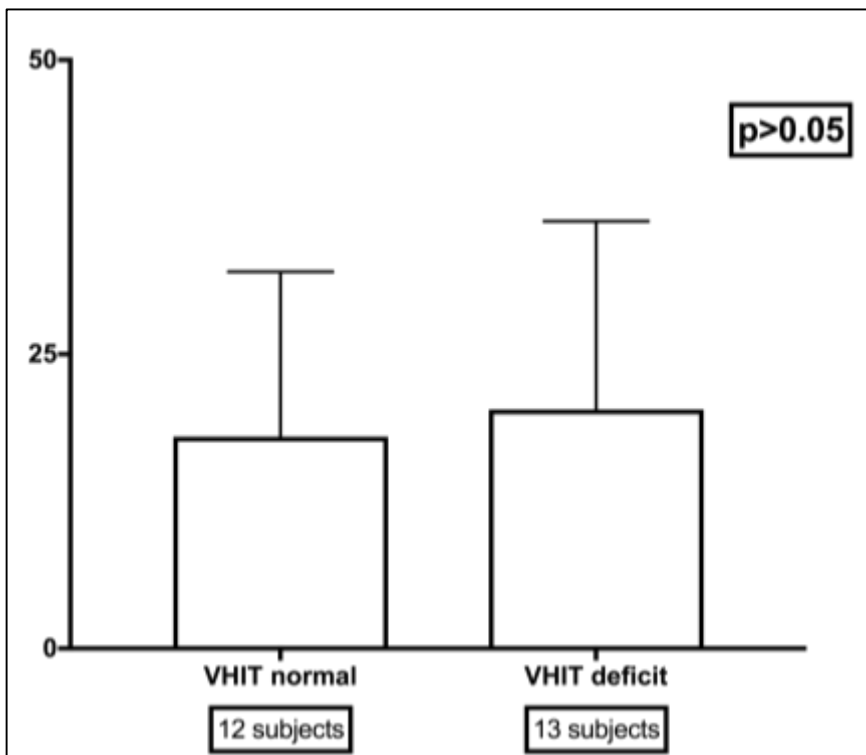


3 MONTHS FOLLOW-UP

DHI TOTAL SCORE

VHIT

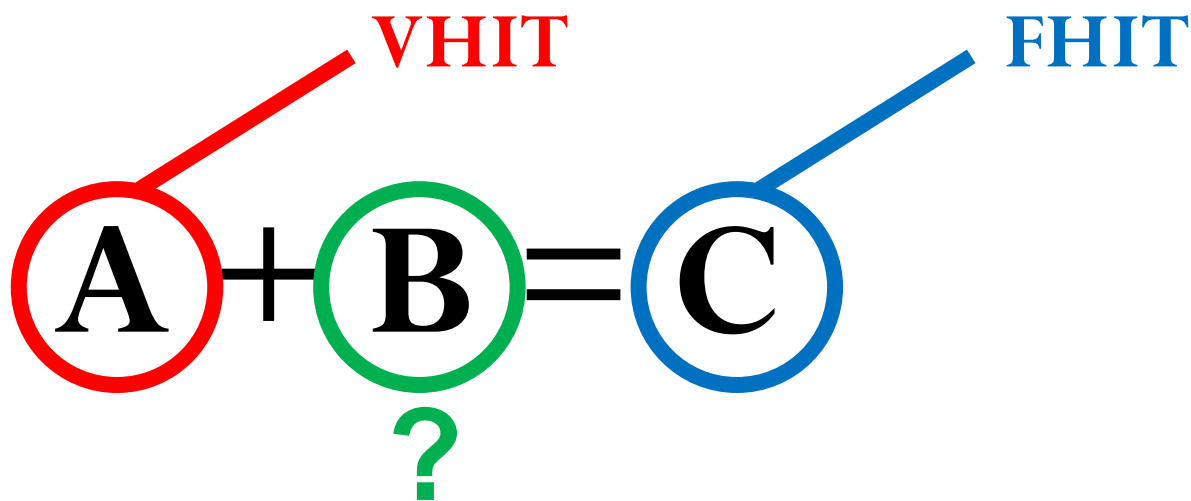
FHIT



DISCUSSION

- **The VHIT and FHIT have similar results in acute and at 3 months follow-up despite contralesional side appears to be slightly more affected at FHIT**
- **5 subjects who showed covert saccades were correctly identified by the FHIT**
 - **The FHIT shows a stronger correlation with DHI (perceived disability) than VHIT** (McCaslin et al. 2014; Patel et al., 2016)
 - **Artifacts are not present in the FHIT while it is not an objective test**

In case you were the last audiologist on an remote island would you prefer to have with you the pure tone or speech audiometry?





THANK YOU